



*Another  
Successful  
Case  
Study  
Made  
Possible by*



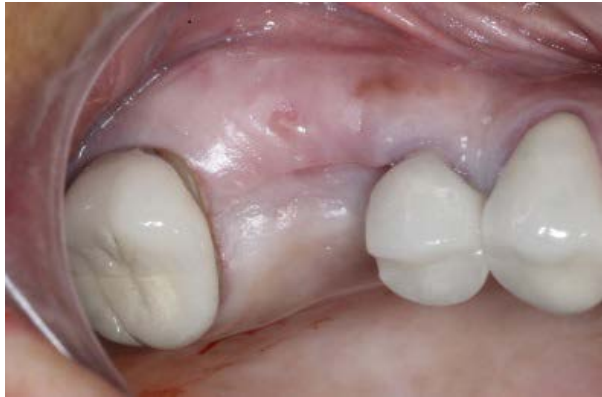# Platform Switching From Beginning To End

By Dr. Kent Hamilton

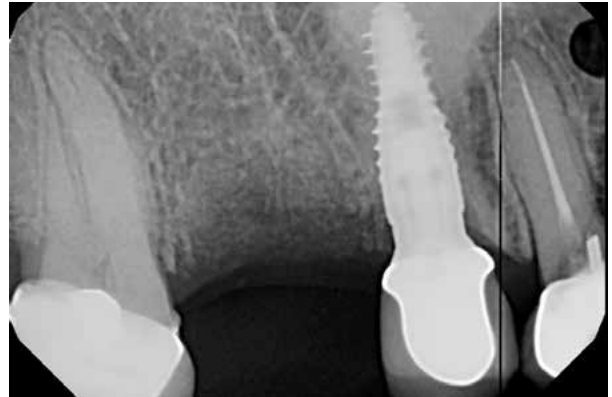## Case Notes

34-year-old female presents with prior Immediate Ritter implant placement on #4 and edentulous #3 post 3month extraction. Patient loves her implant on #4 and now wishes to have an implant for #3. Clinical and Radiographic examination revealed bone is ready for Ritter implant placement #3 and determined 4.3x11.5 was the appropriate size.

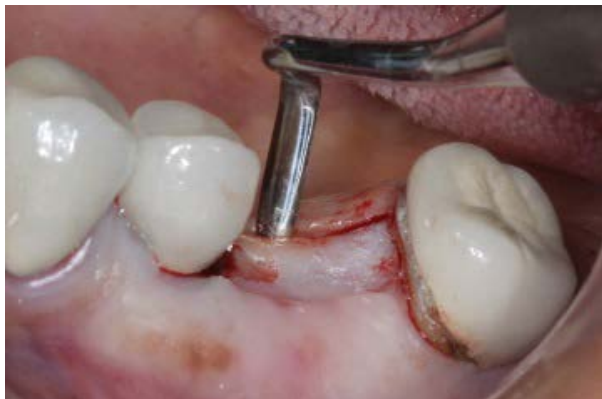



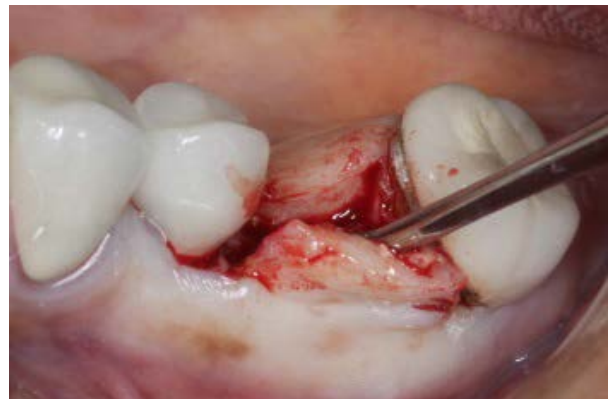
1 - Three Months Post Bone Graft



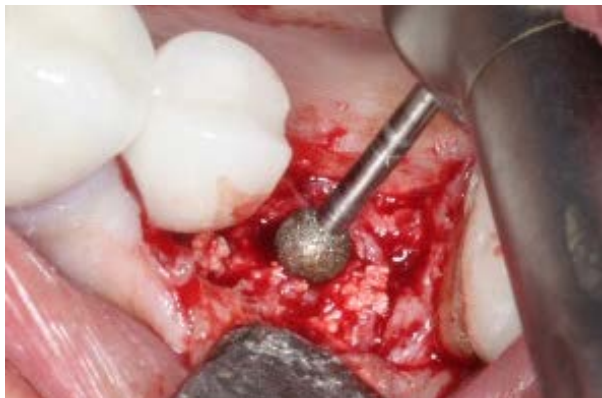2 - Three Months Post Extraction



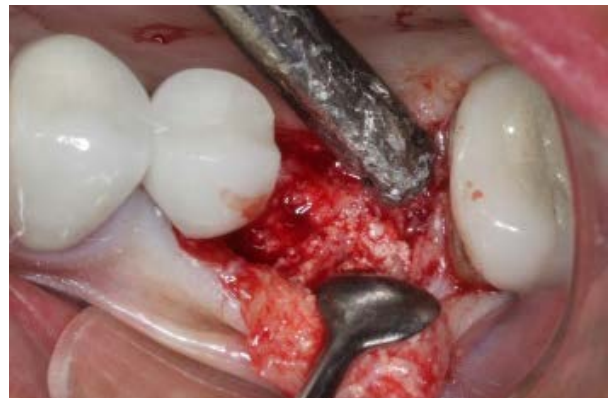3 - Flap Reflection



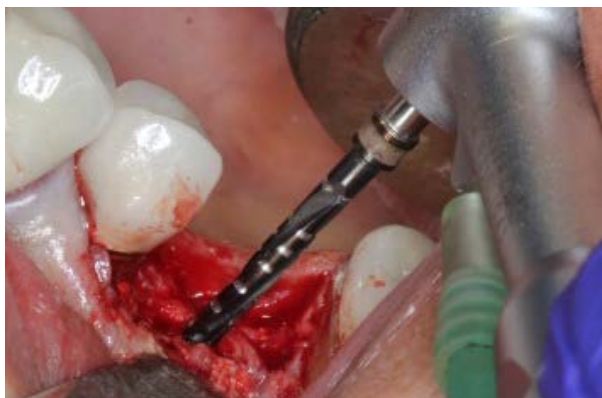4 - Flap Reflection



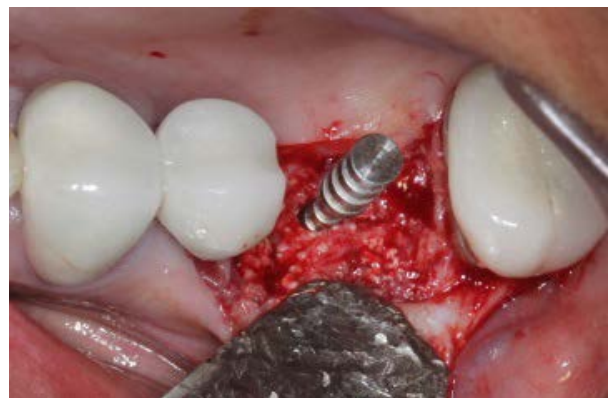5 - Initial Alveoplasty



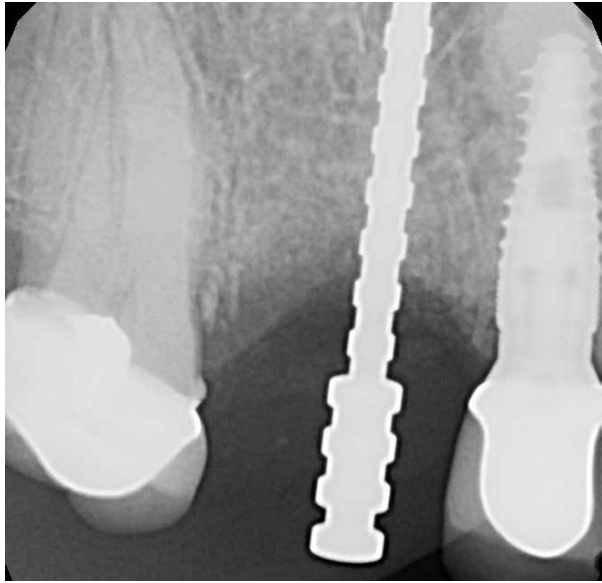
6 - Visualization of Ridge



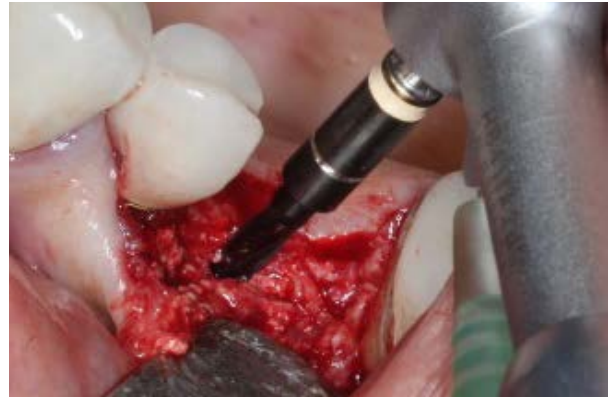7 - Three-in-One Pilot Drill



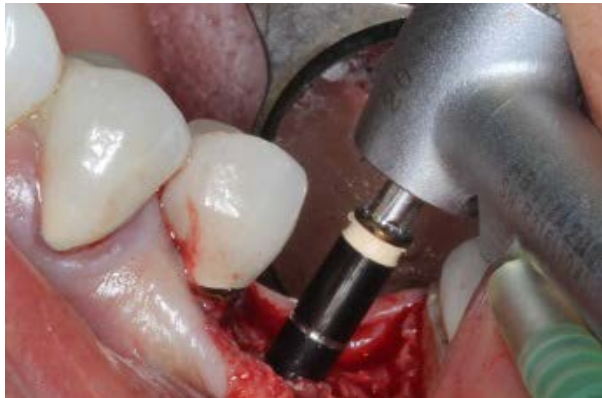8 - Depth and Angle Indicator



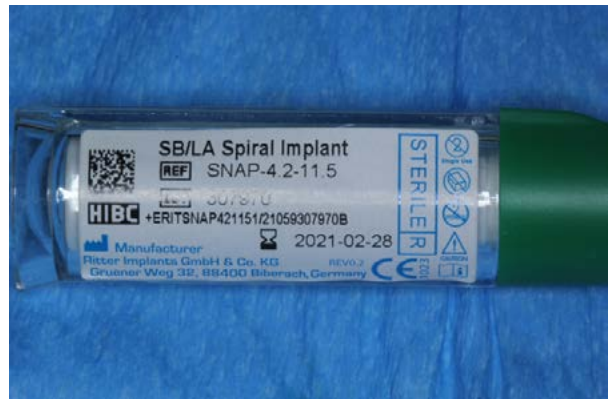9 - Angulation and Depth Pin



10 - 11.5 Drill with Stop



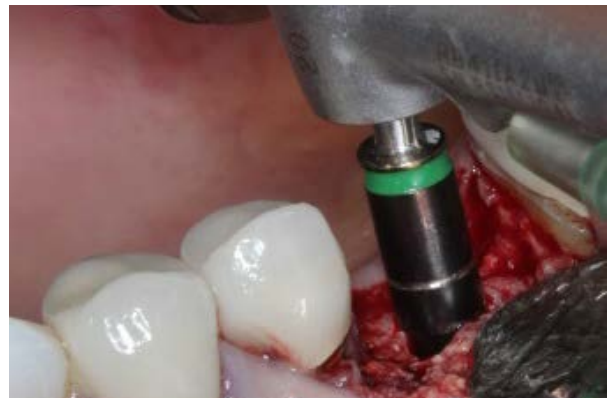11 - Drill to Depth



12 - Green Stopper Matches Green Band



13 - Implant



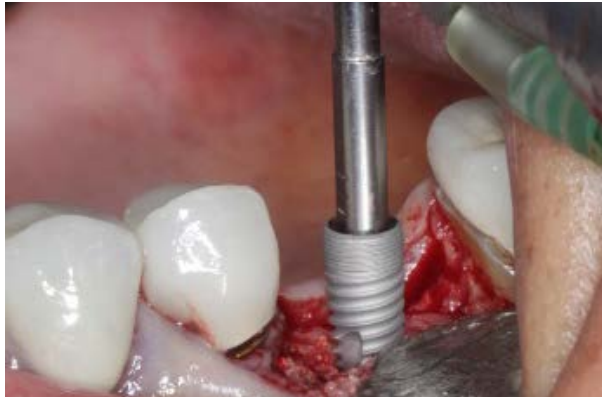14 - 3mm Reference Marking



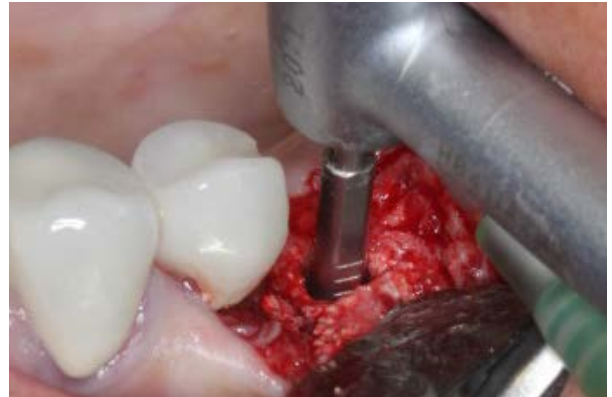
15 - Mountless Implant Delivery



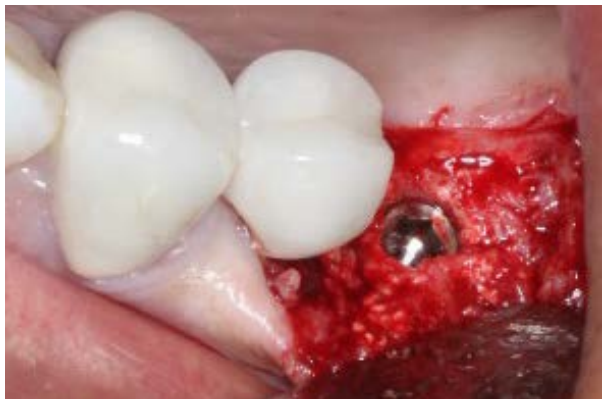16 - Implant Driver



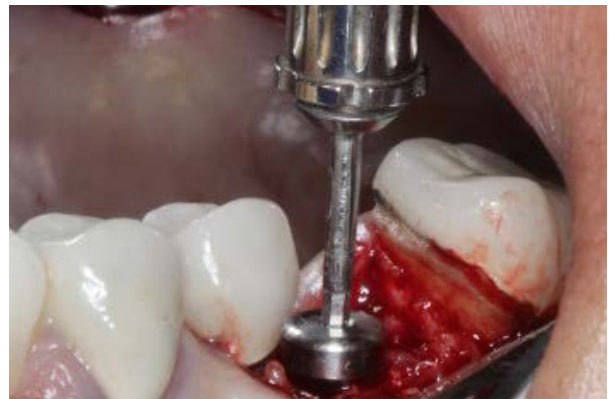17 - Implant Placement



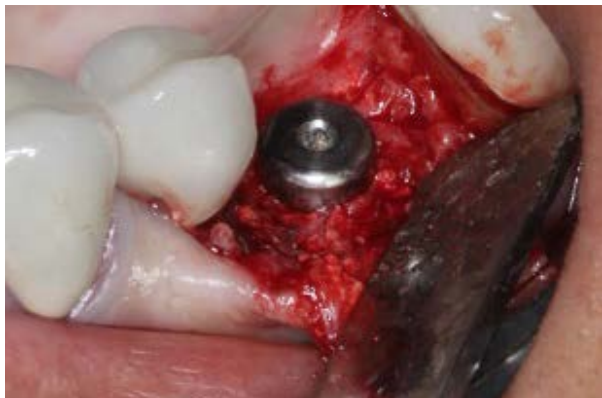18 - Depth Markings on Implant Driver



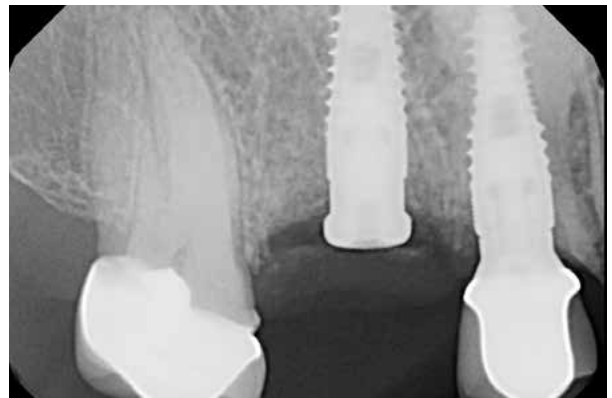19 - Implant Seated



20 - Healing Cap Placement



21 - Healing Cap Seated



22 - Step Healing Abutment