



*Another  
Successful  
Case  
Study  
Made  
Possible by*



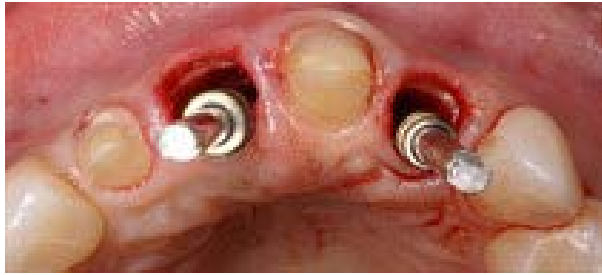# Double Pet In Anterior Maxilla At 4 Years With Ritter Spiral

By Dr. Maurice Salama

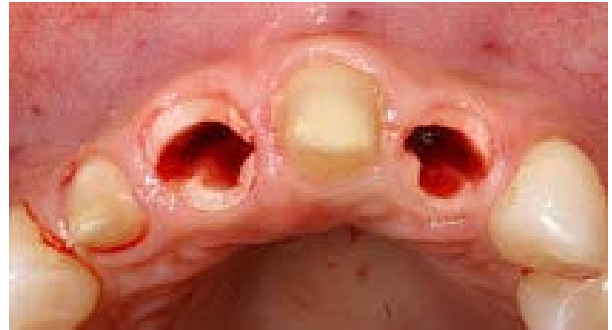## Case Notes

Idiopathic Root Resorption and ankylosis of 2 anterior teeth with very THIN Biotype treated with PET NO GRAFTING and Ritter Spiral Implants to preserve ridge form. 4 years post op shown.

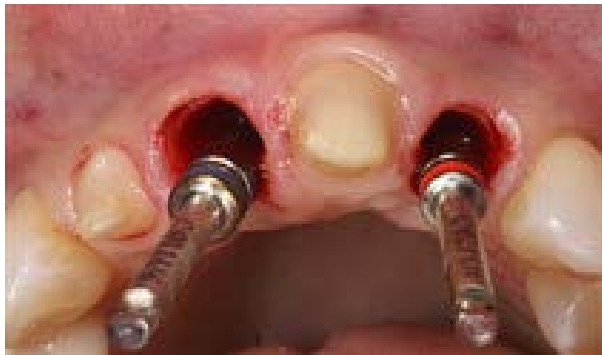



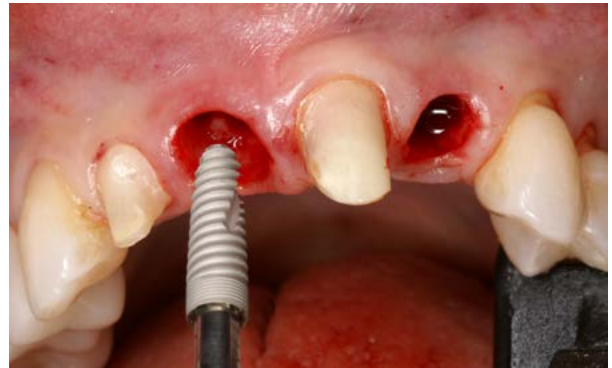1 - Socket Shield



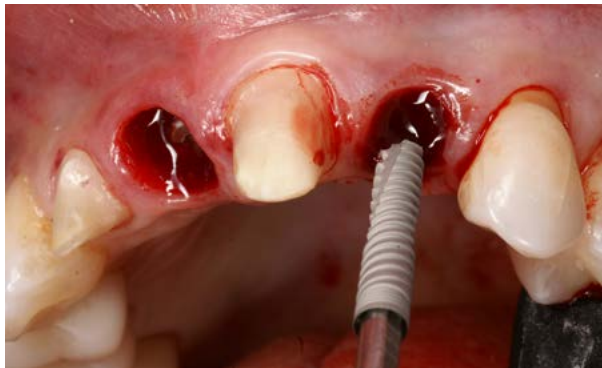2 - SS Preps



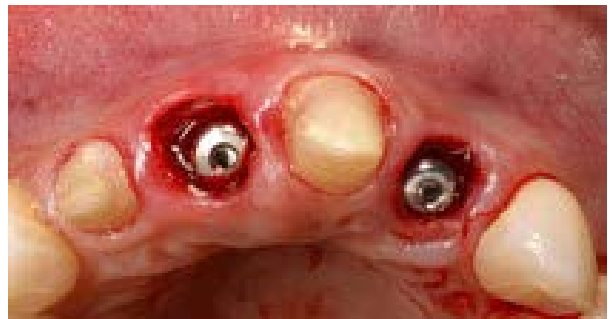
3 - After Osteotomies



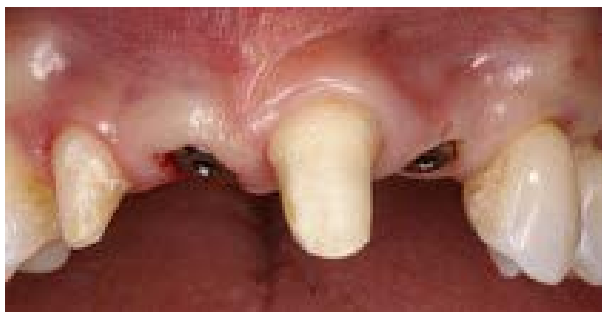4 - Implant Insertion Ritter Spiral



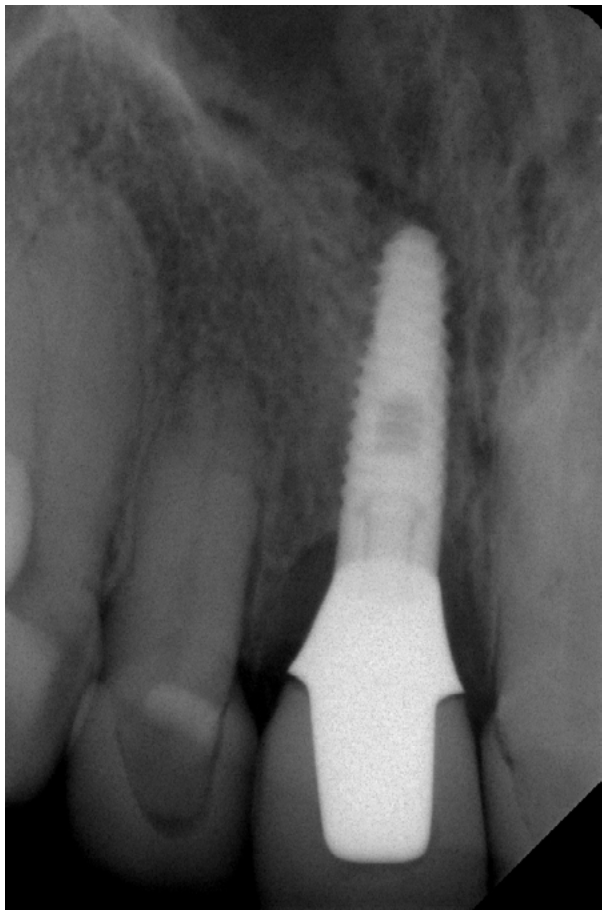
5 - Implant Insertion Ritter Spiral



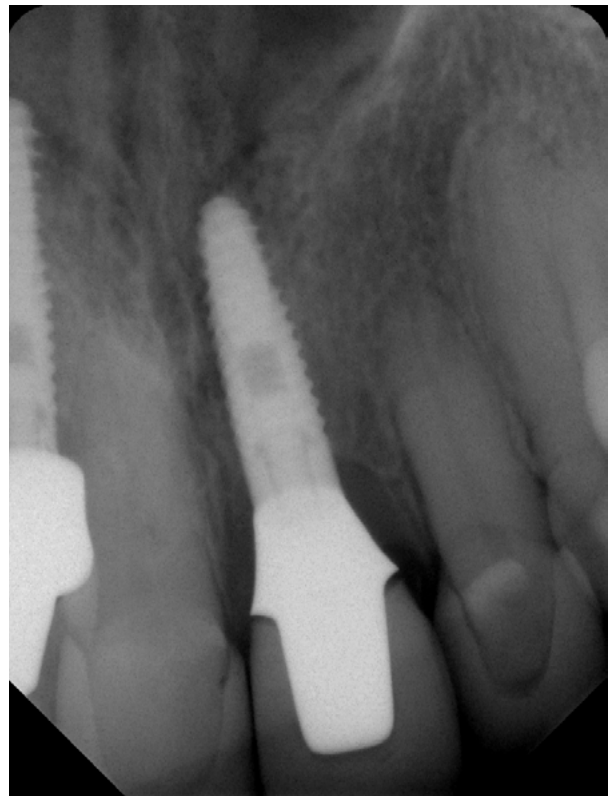6 - No Bone Graft



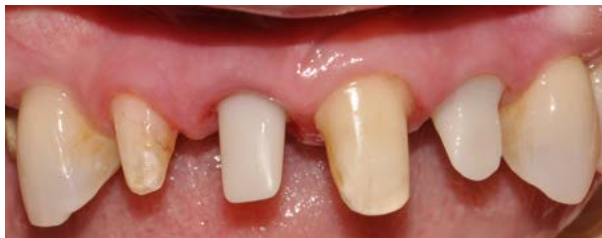7 - After Healing 3 Months



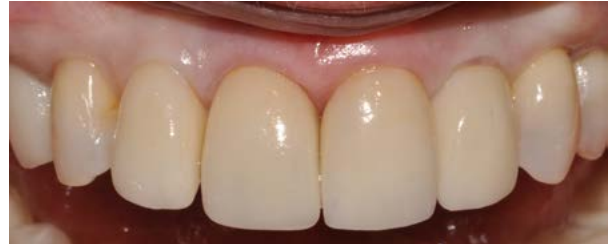8 - X-Ray



9 - X-Ray



10 - Ceramic Abutments



11 - Final at 3 Years