



*Another  
Successful*  
**Case  
Study**  
*Made  
Possible by*



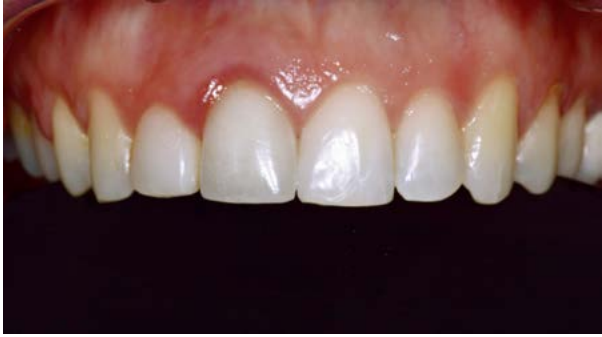# Immediate Extraction With Ridge Preservation

By Dr. Manuel De la Rosa (Periodontist)  
and Dr. Roberto Anzaldúa (Prosthodontist)

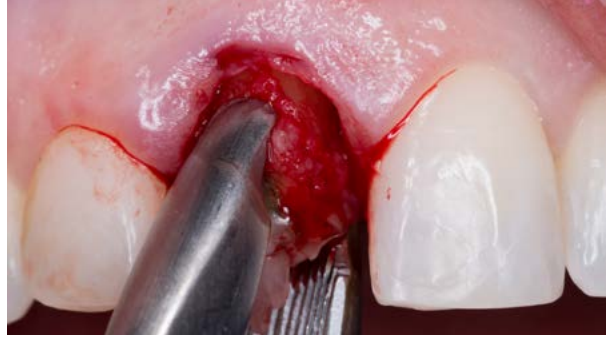## Case Notes

Patient presented with short root and periapical lesion and a poor prosthetic prognosis. Immediate extraction and implant placement was performed combined with osseous grafting and PRF. A Maryland type of provisional restoration was performed initially, and after osseointegration was performed, a direct restoration was performed to guide the soft tissues. Finally definite crown was performed with the Ritter Prosthetic system. Patient was extremely happy with the results of treatment.

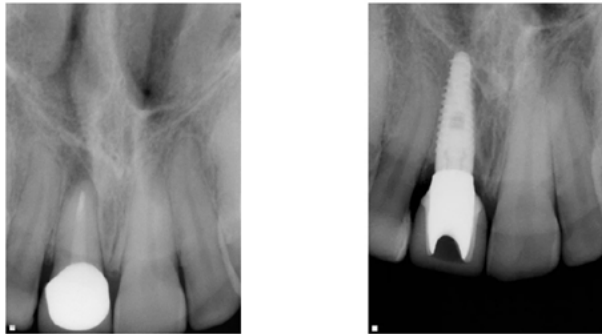




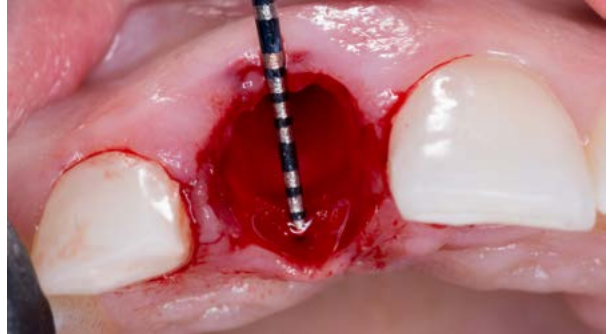1 - Initial



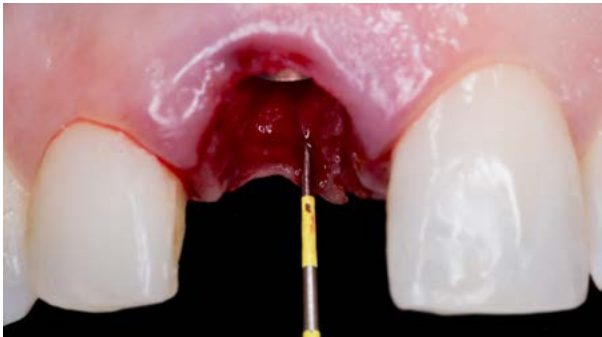2 - Extraction



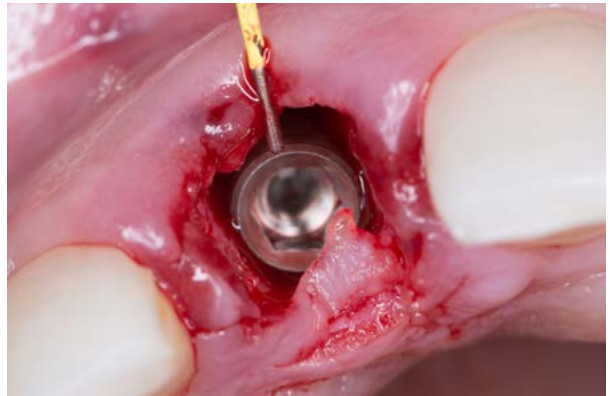3 - X-Ray Comparison



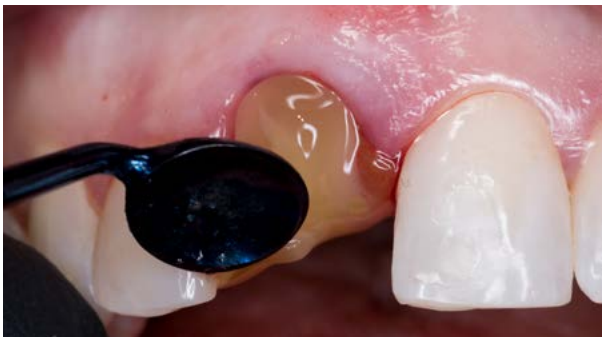4 - Alveolus



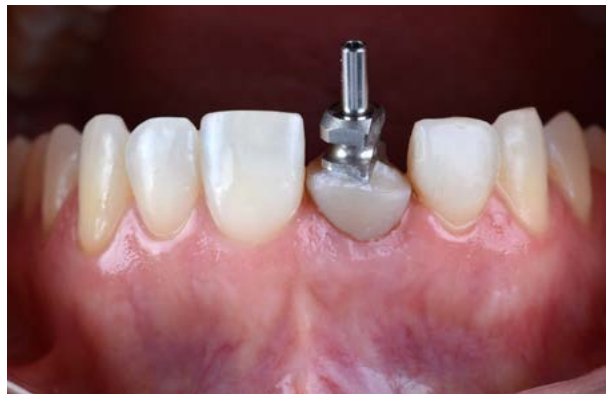5 - Implant Depth



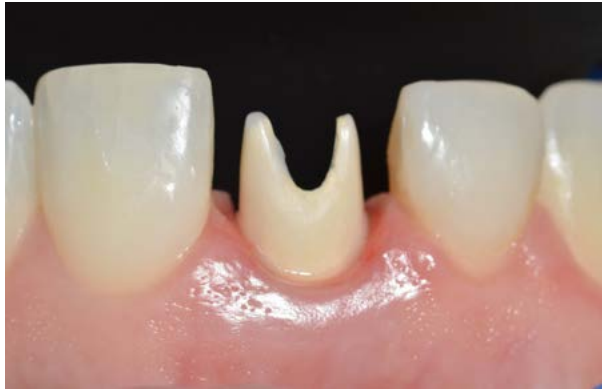6 - Implant Width



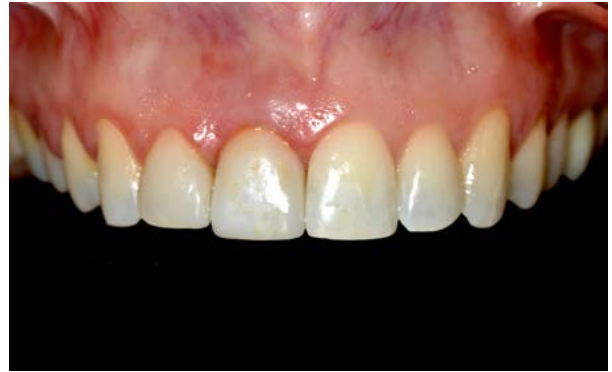7 - PRF



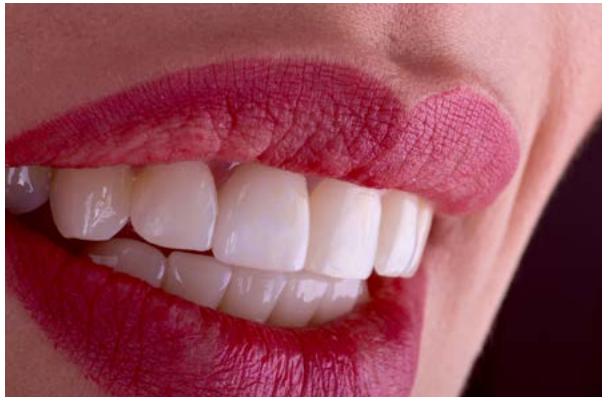8 - Impression Coping



9 - Abutment Prep



10 - Final Crown



11 - Smile