

# Ritter Dental Implants

Clinical Cases

*Dr. Alejandro Freer*

ESTHETIC & IMPLANT DENTISTRY

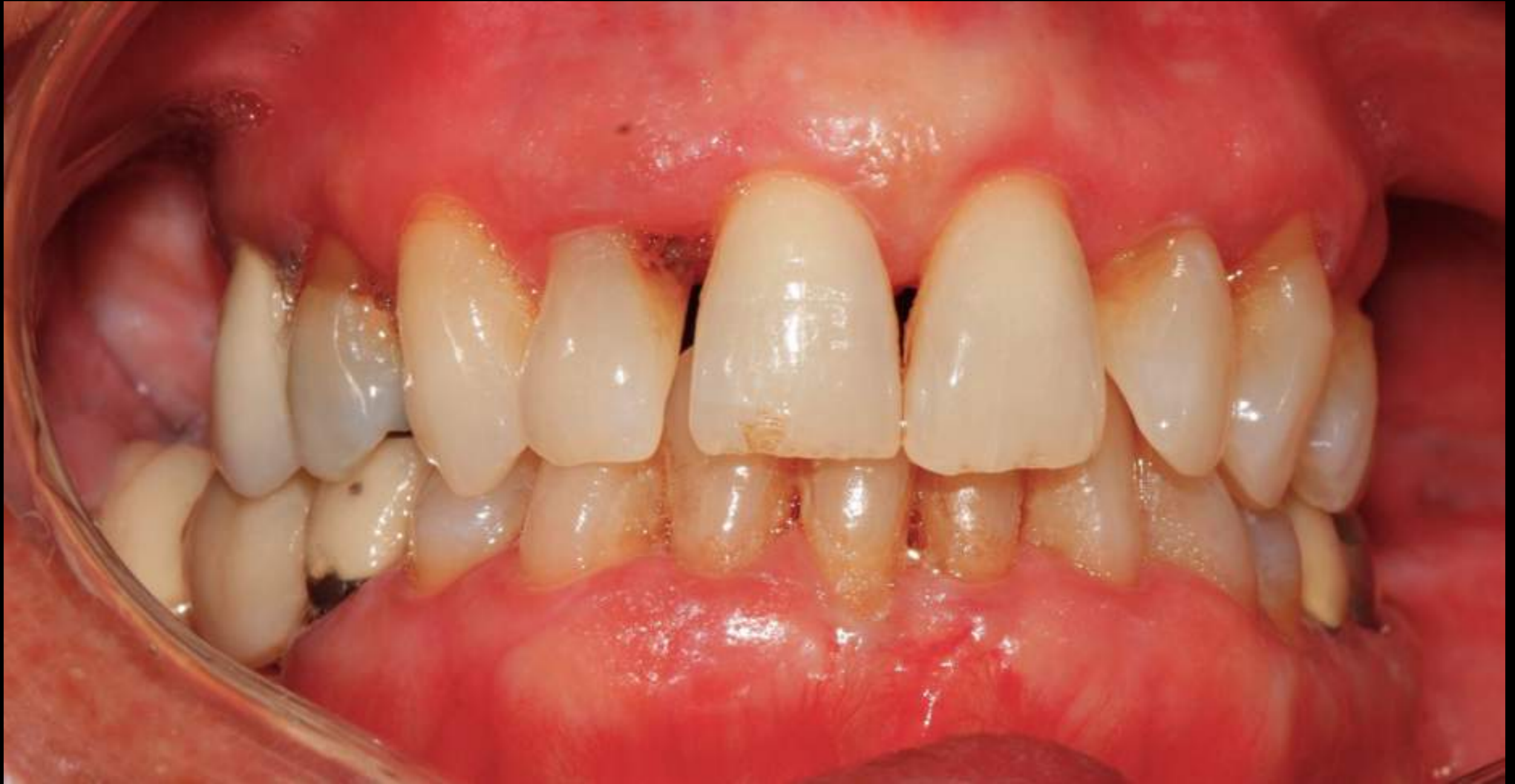# Upper All on 8 and Lower All on 6



*Dr. Alejandro Freer*

ESTHETIC & IMPLANT DENTISTRY

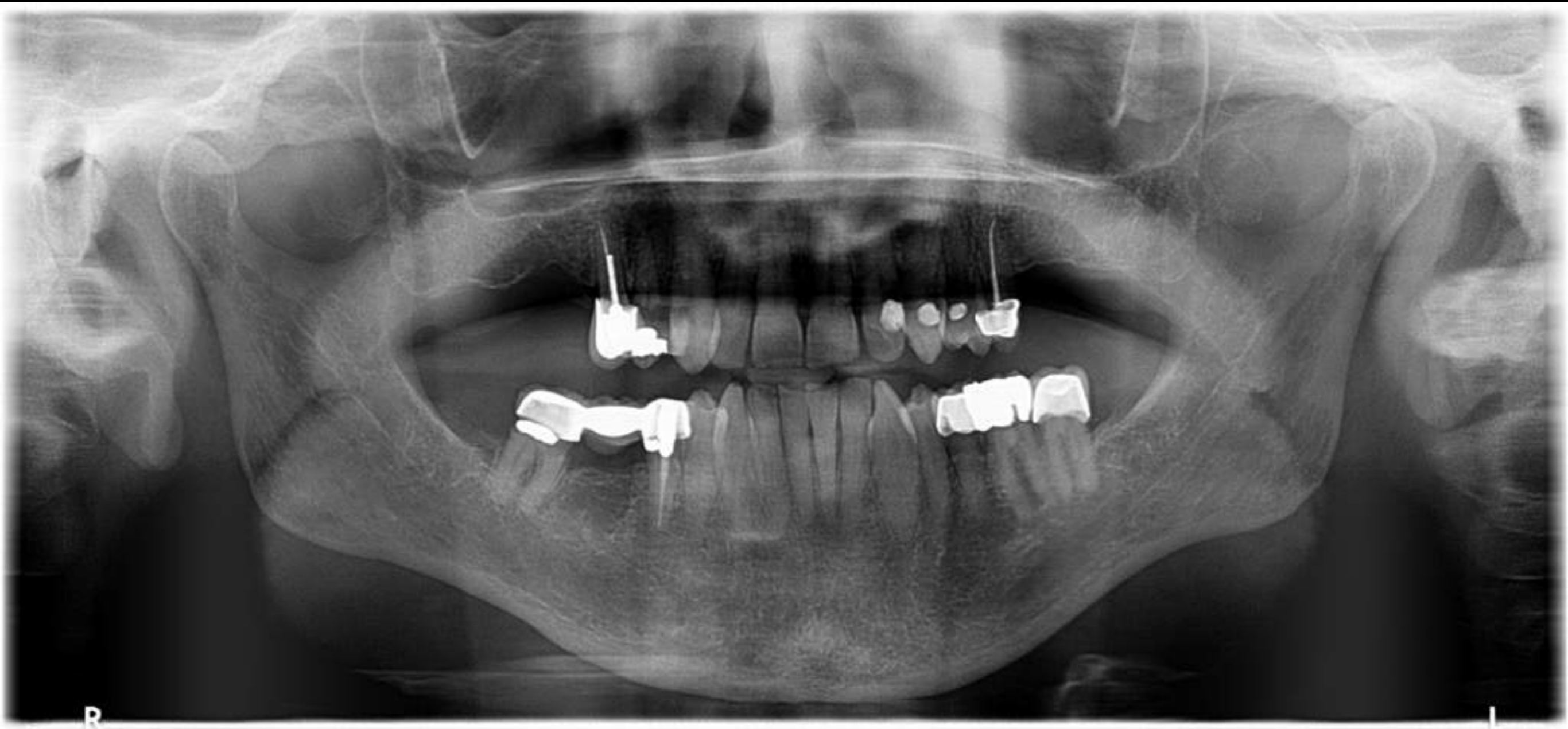
# Initial Case



*Dr. Alejandro Freer*

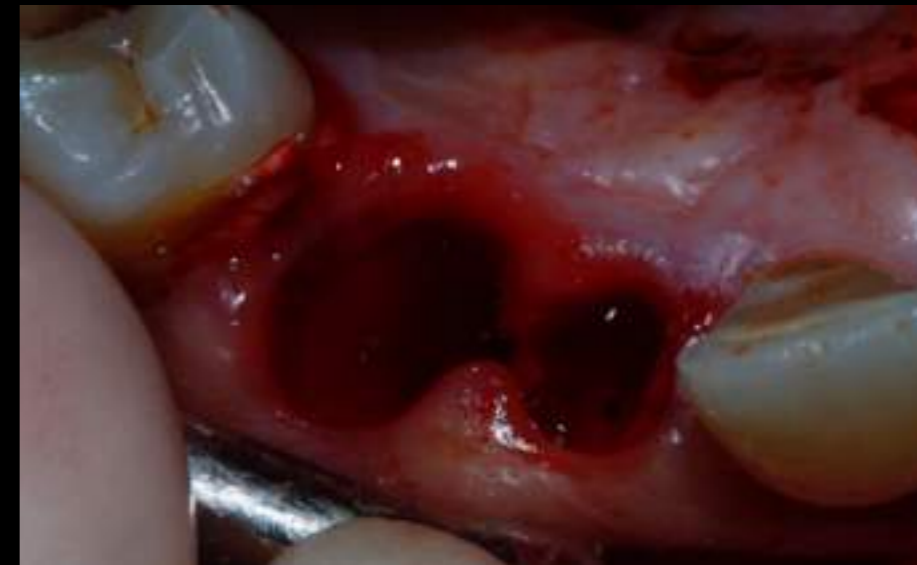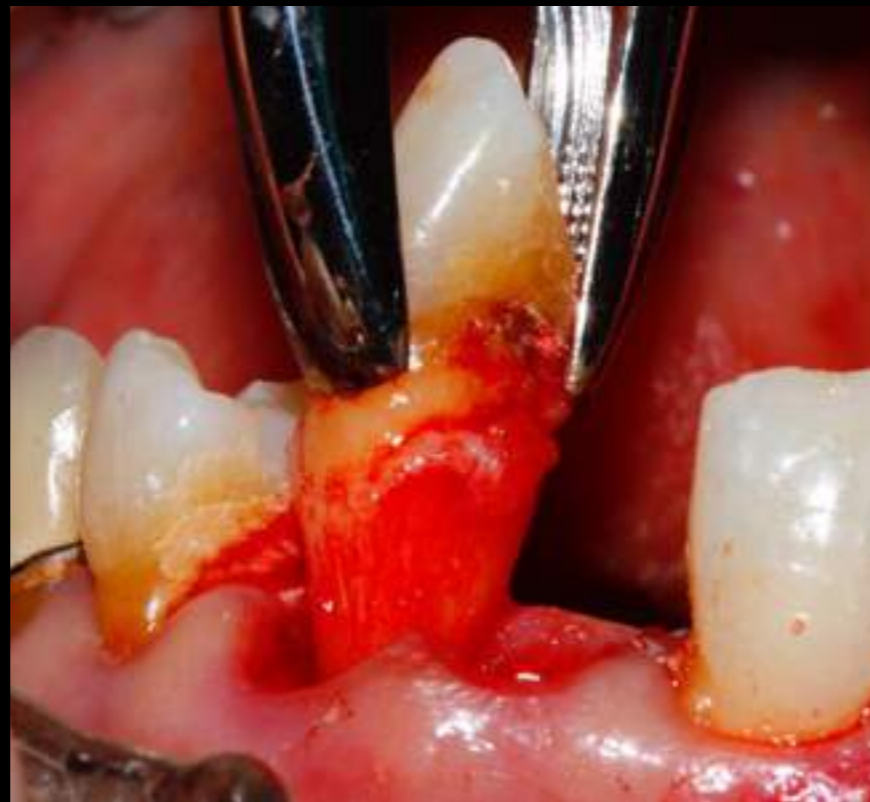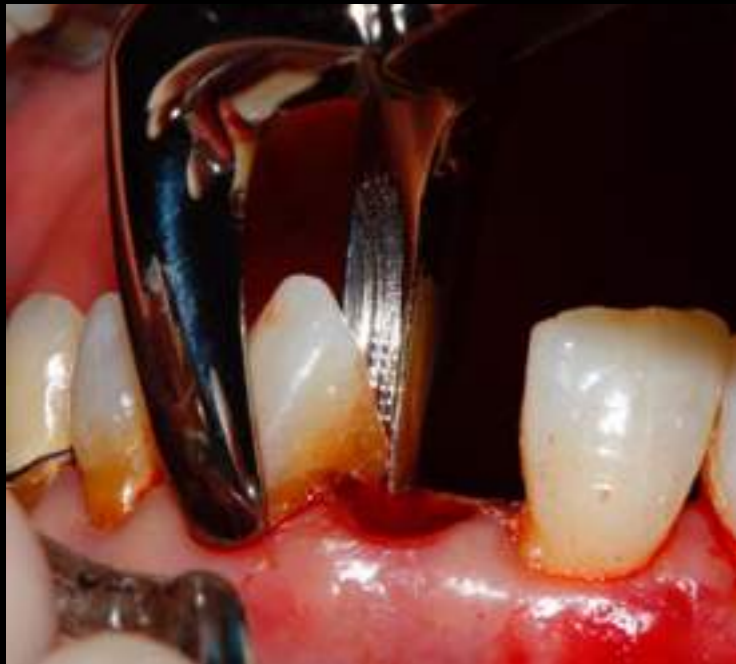ESTHETIC & IMPLANT DENTISTRY

Panoramic X ray



# Surgical placement of Implants

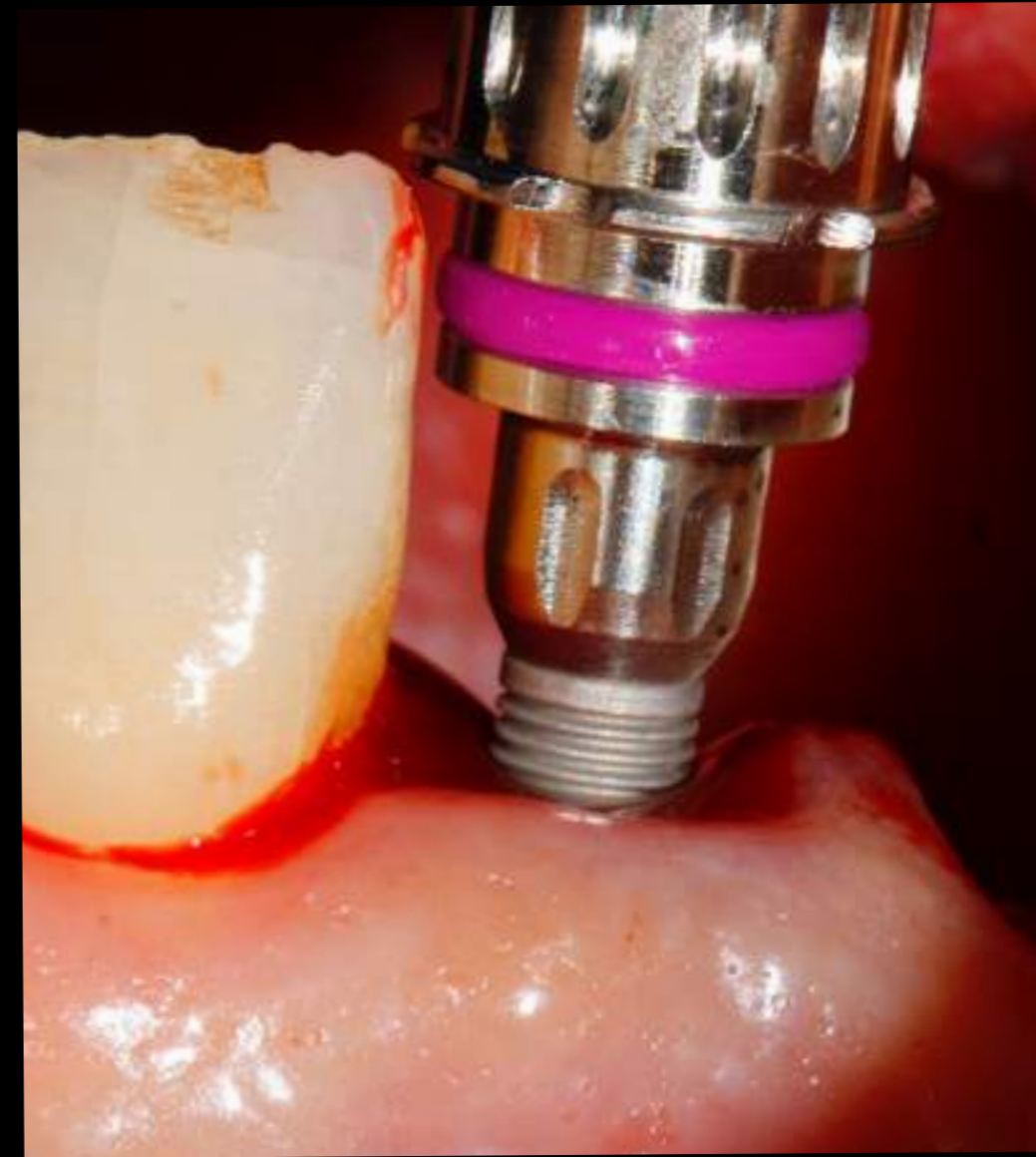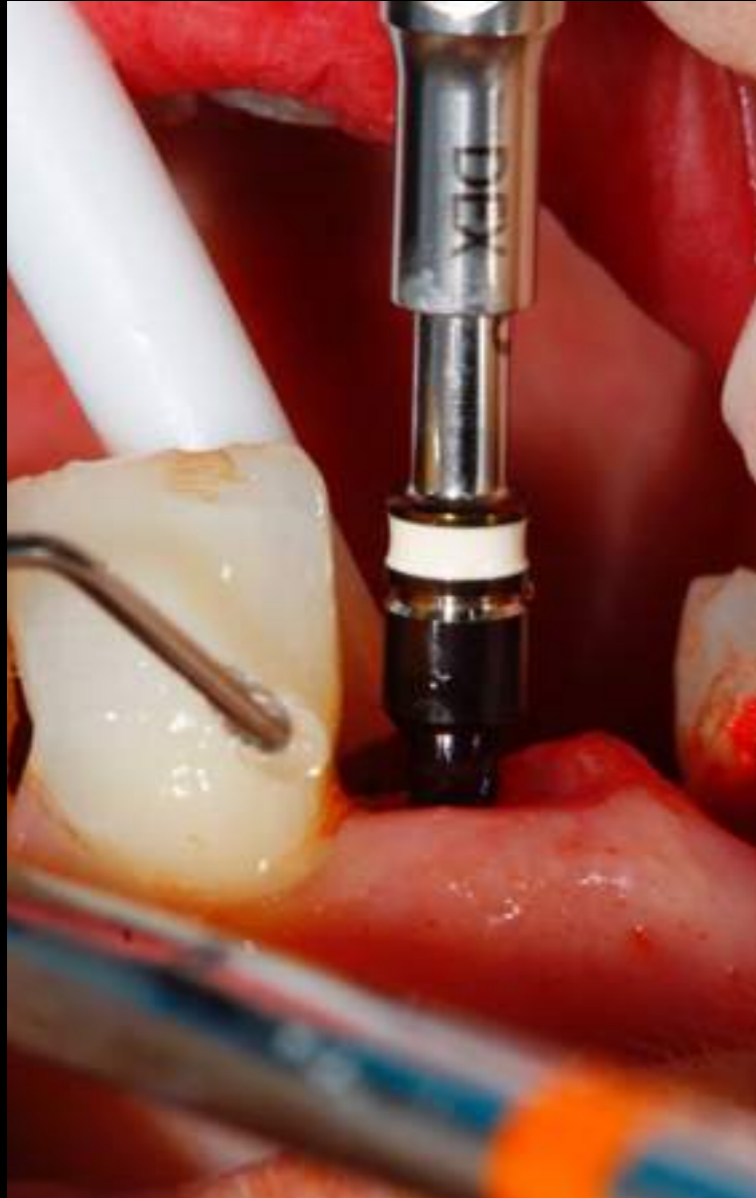## Atraumatic Extraction



*Dr. Alejandro Freer*

ESTHETIC & IMPLANT DENTISTRY

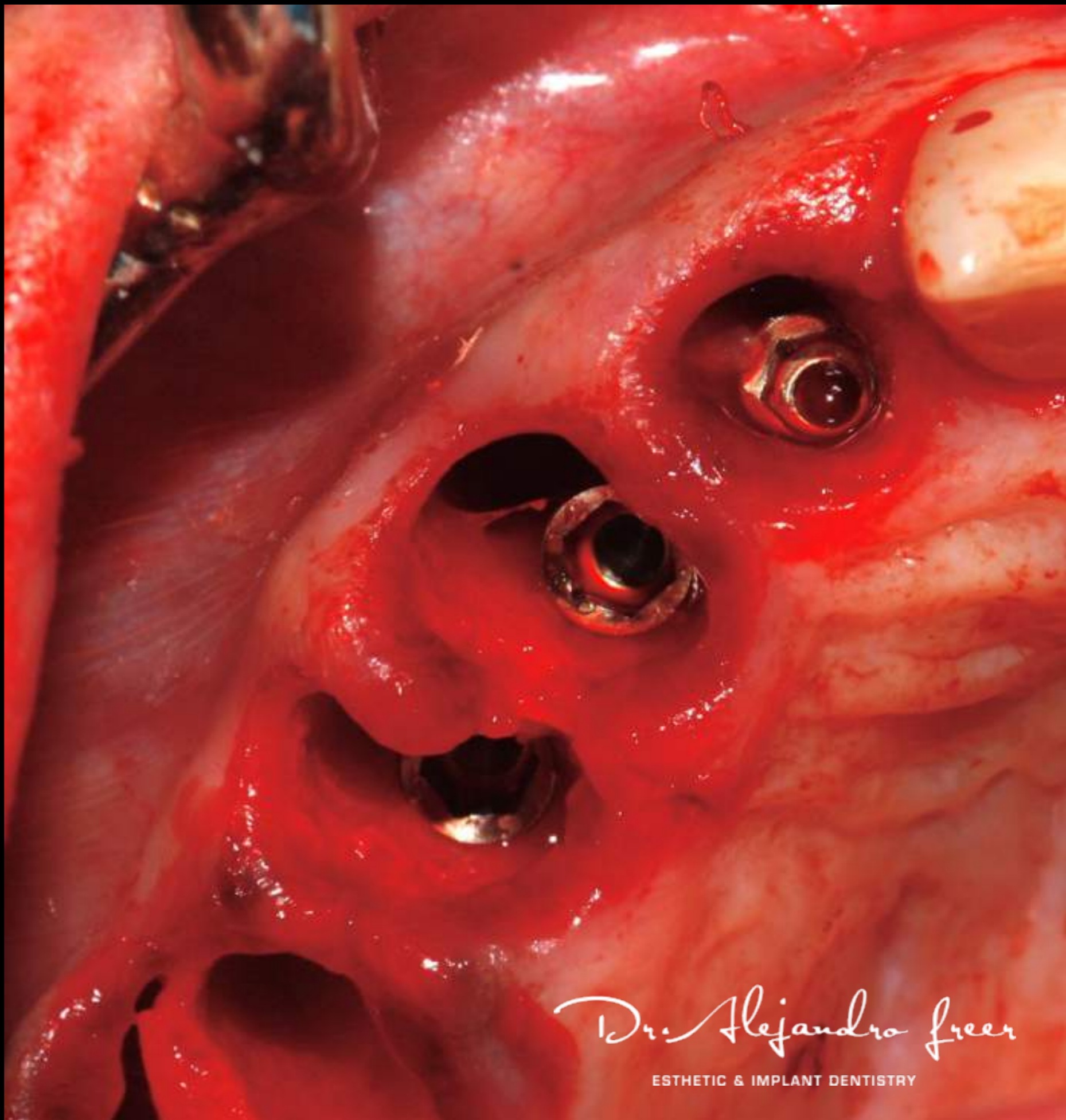
# Immediate Implant Placement



*Dr. Alejandro Freer*

ESTHETIC & IMPLANT DENTISTRY

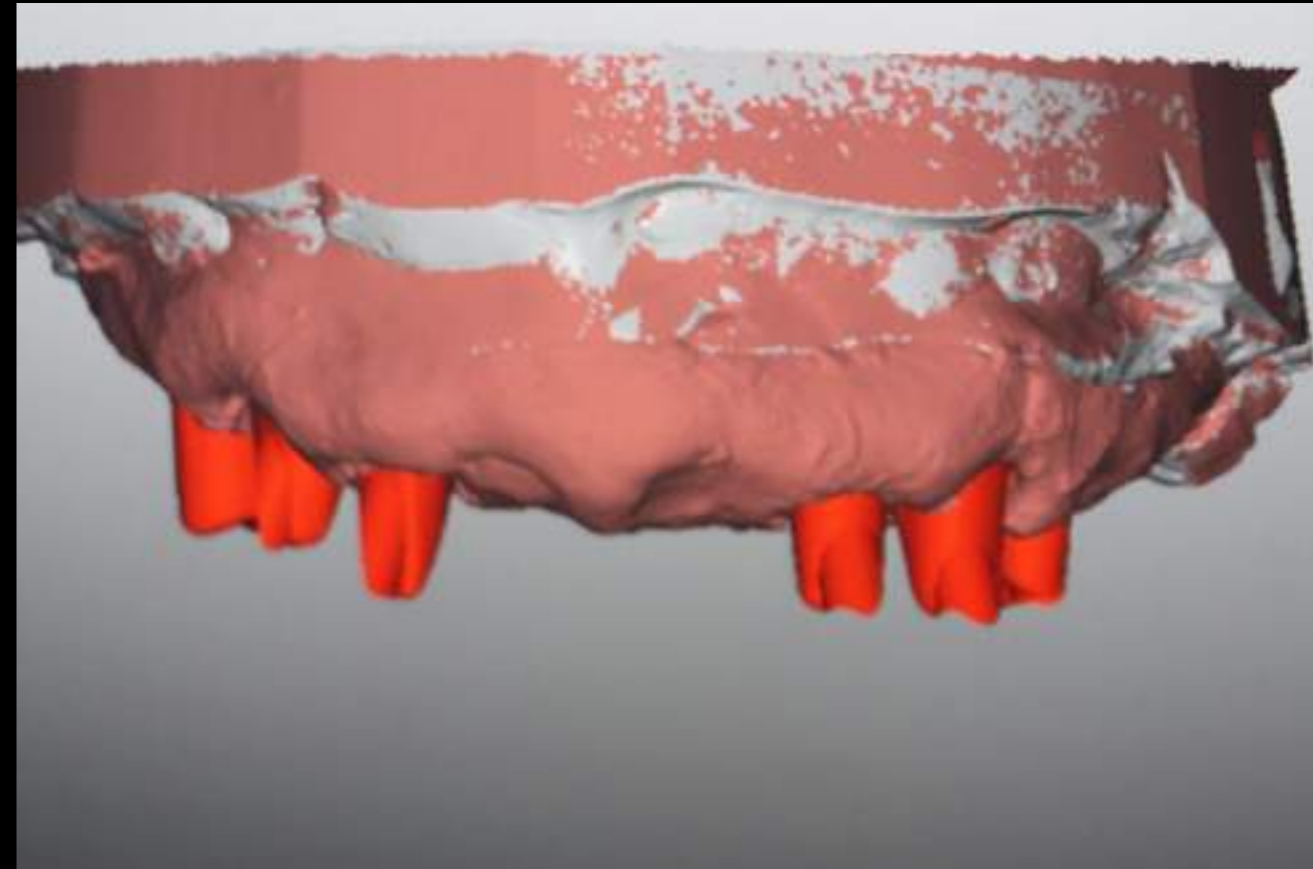
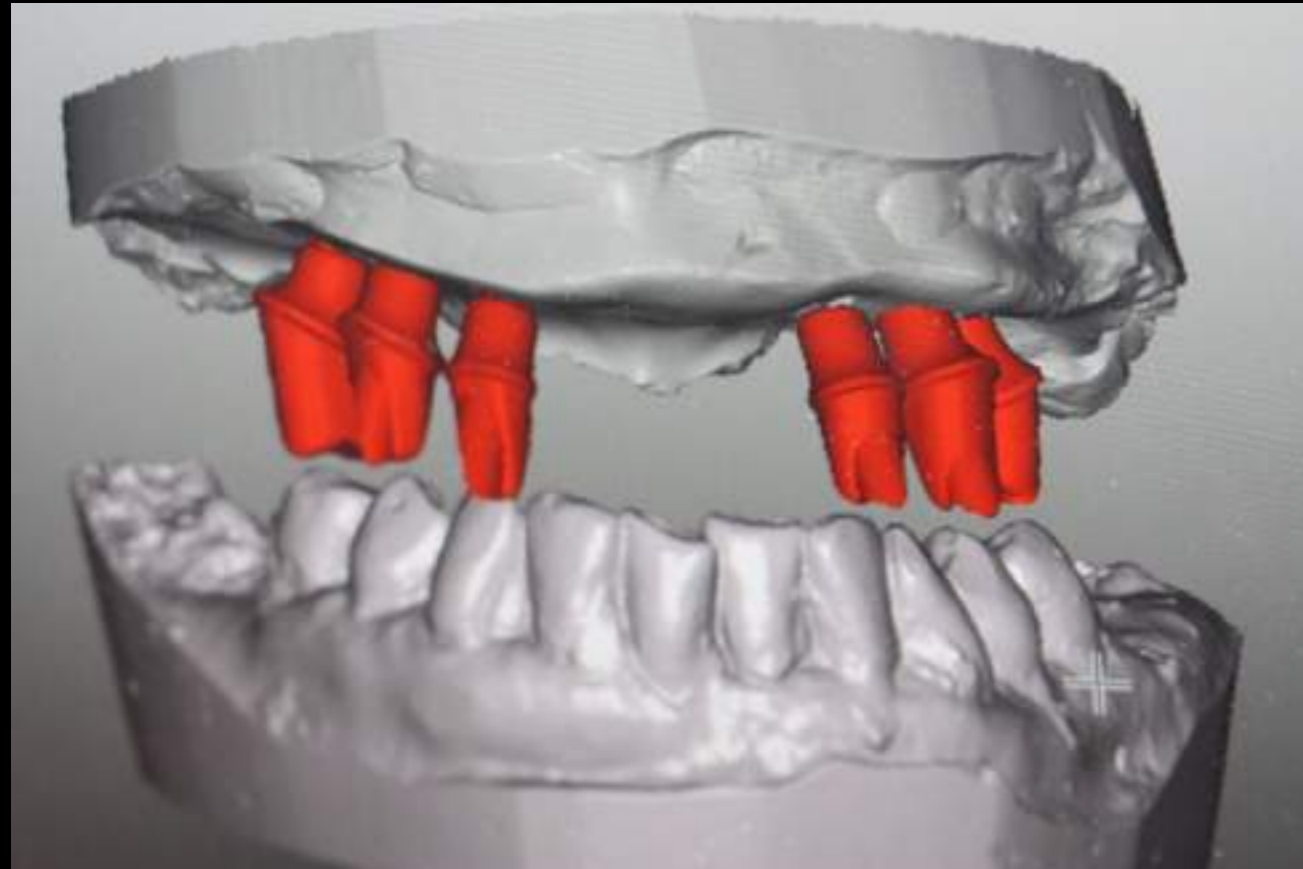
P  
A  
L  
A  
T  
A  
L  
  
P  
L  
A  
C  
E  
M  
E  
N  
T



*Dr. Alejandro Freer*

ESTHETIC & IMPLANT DENTISTRY

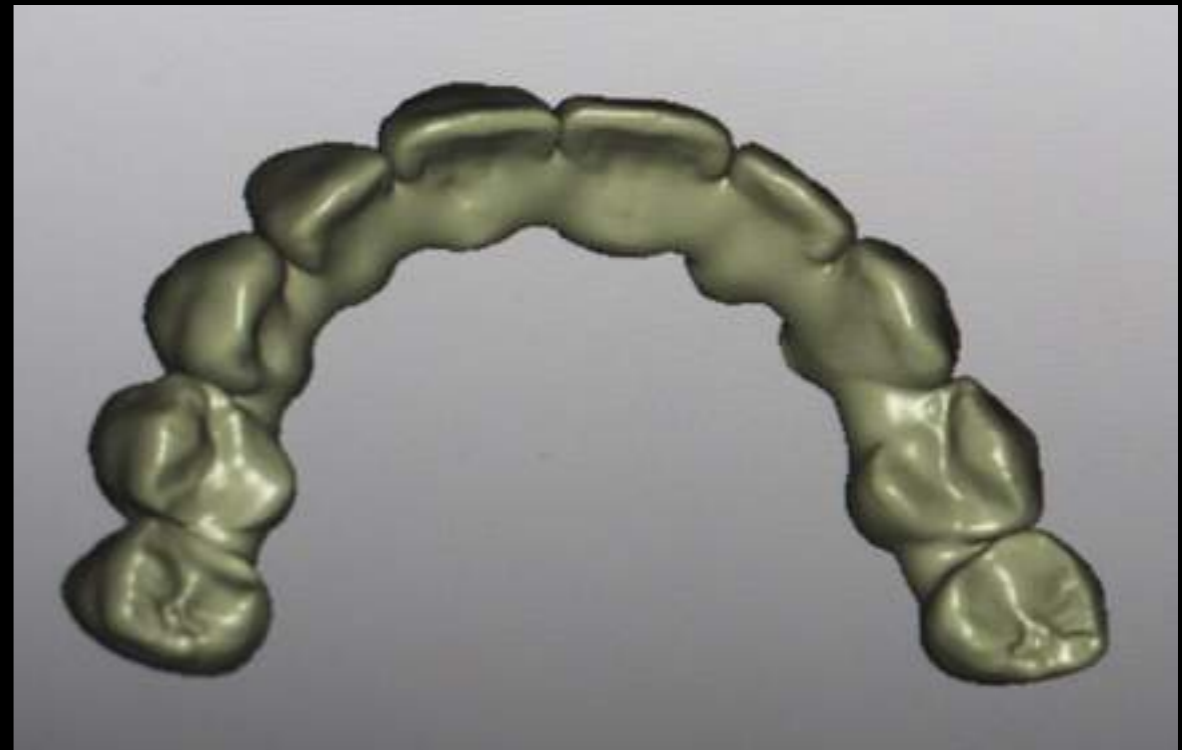
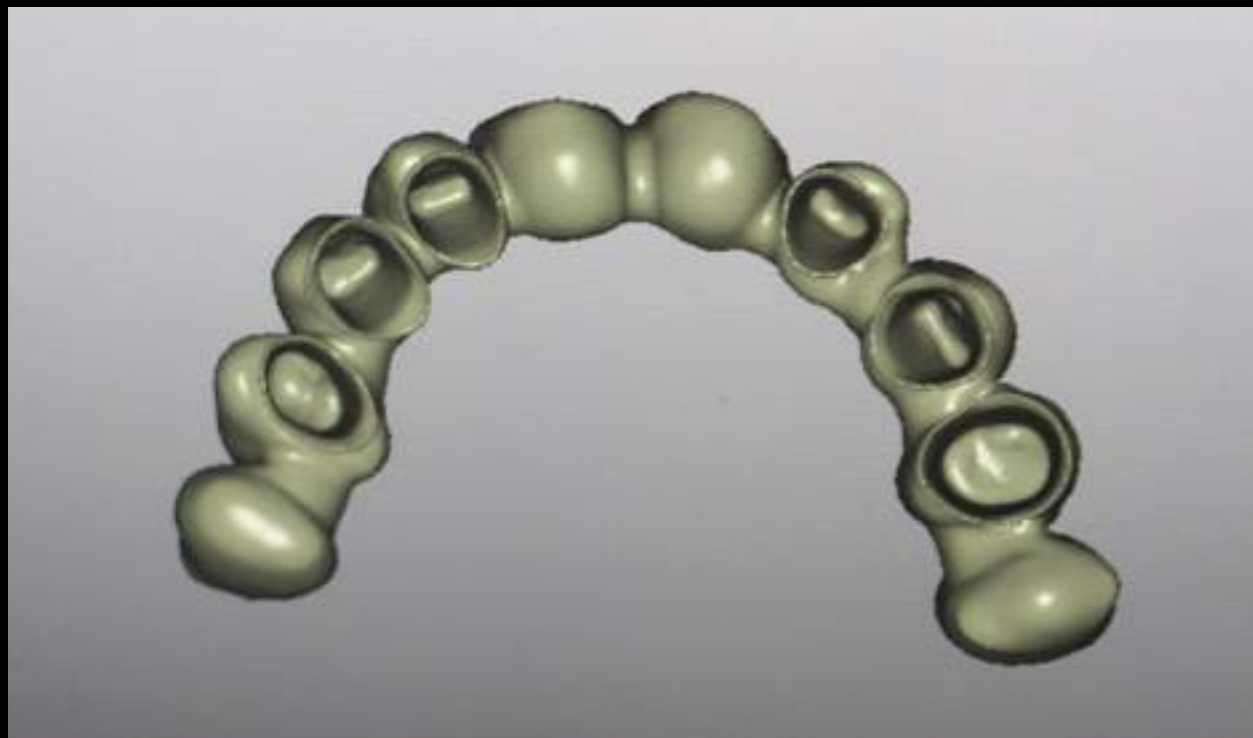
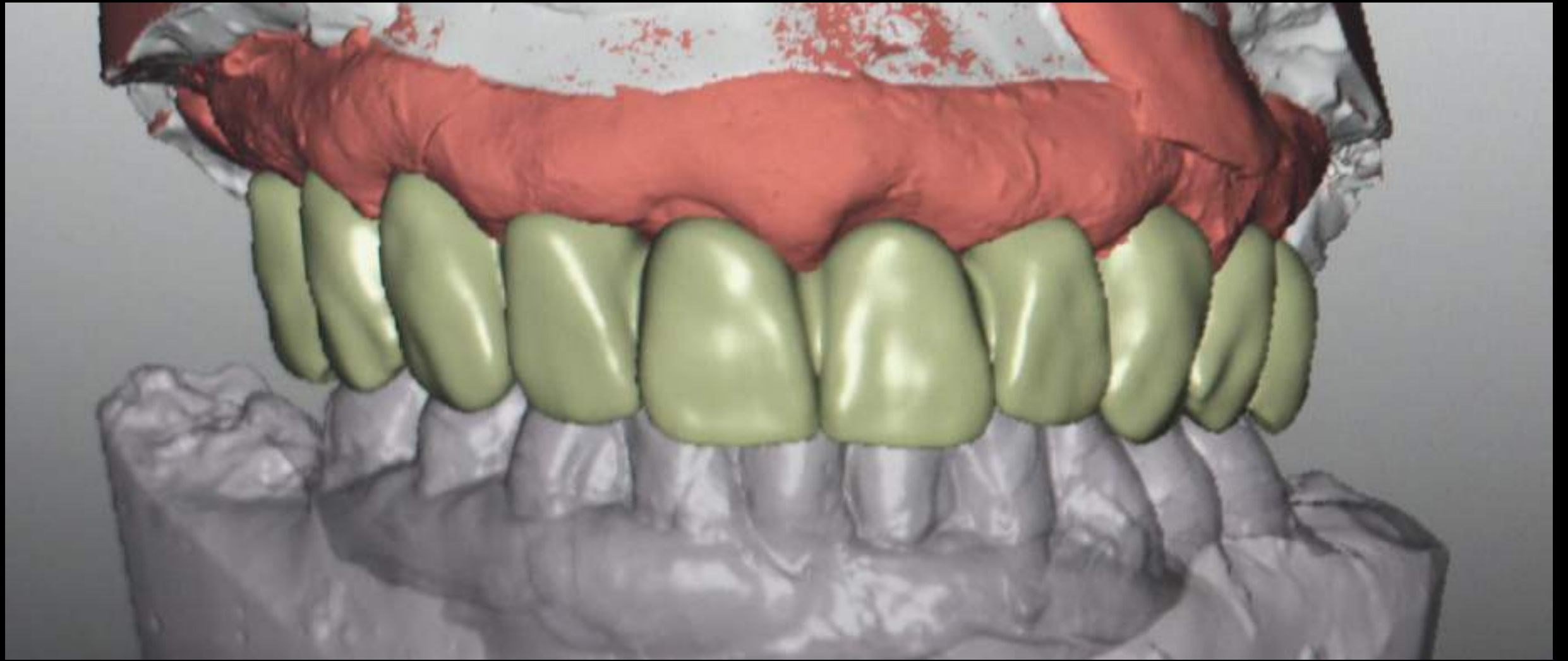
# CAD CAM DESING ZIRKONZAHN M1




*Dr. Alejandro Freer*

ESTHETIC & IMPLANT DENTISTRY







*Dr. Alejandro Freer*

ESTHETIC & IMPLANT DENTISTRY

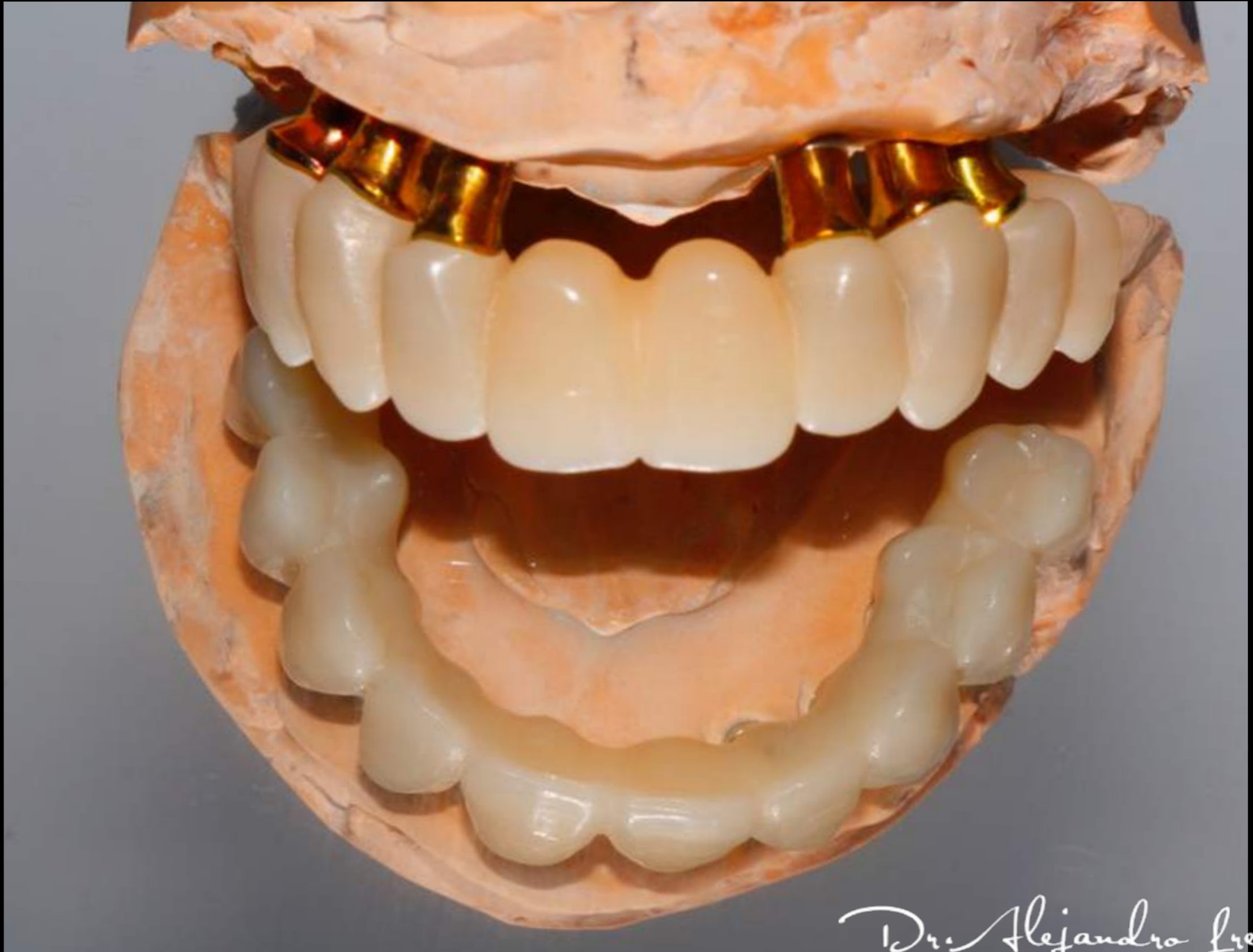Cement retain provisional using 6 milled titanium abutments and a PMMA structure. We use 6 implants for the immediate loading, the 2 posterior implants we left them without load.



*Dr. Alejandro Freer*

ESTHETIC & IMPLANT DENTISTRY

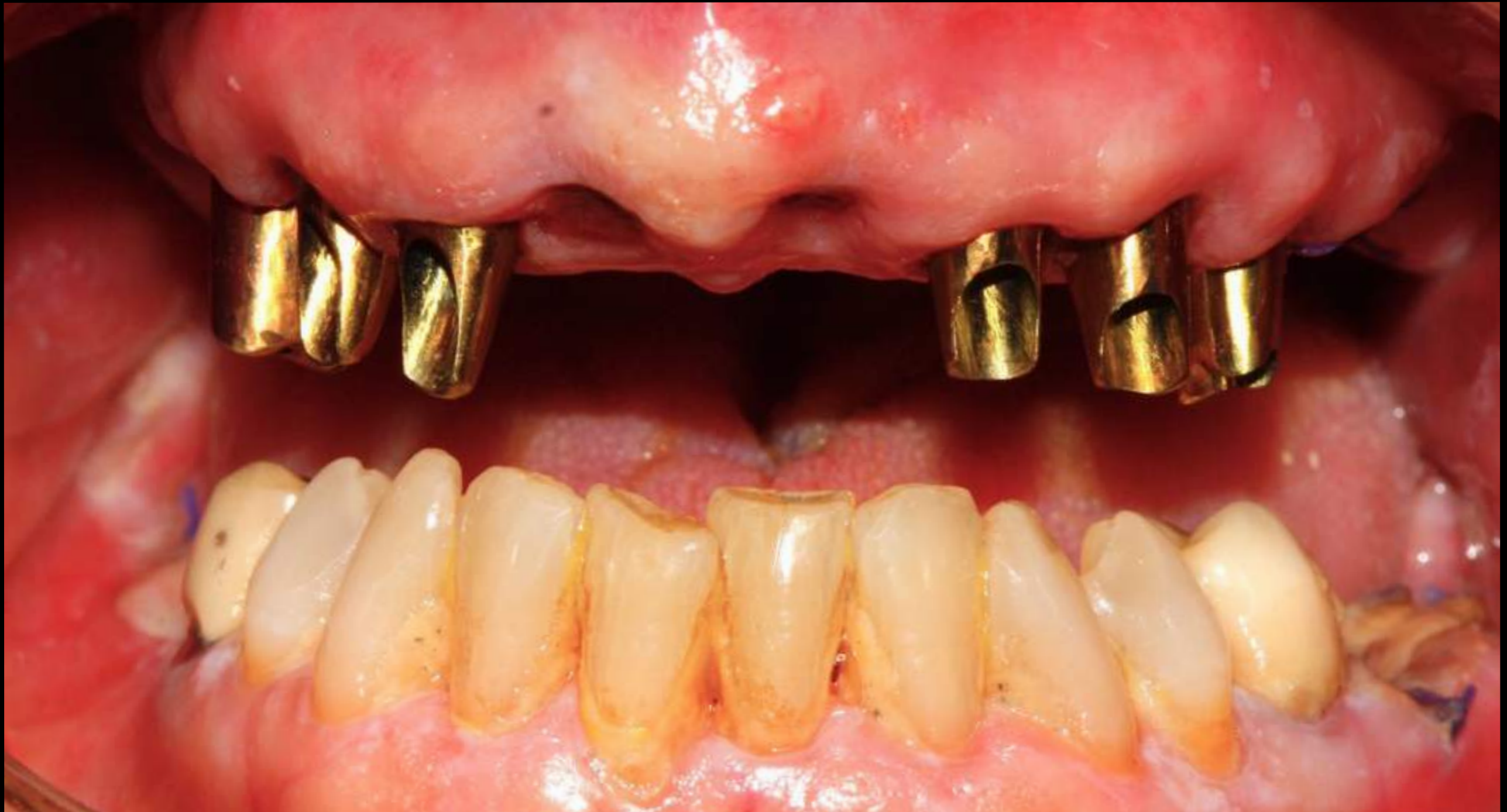P  
M  
M  
A  
S  
T  
R  
U  
C  
T  
U  
R  
E



*Dr. Alejandro Freer*

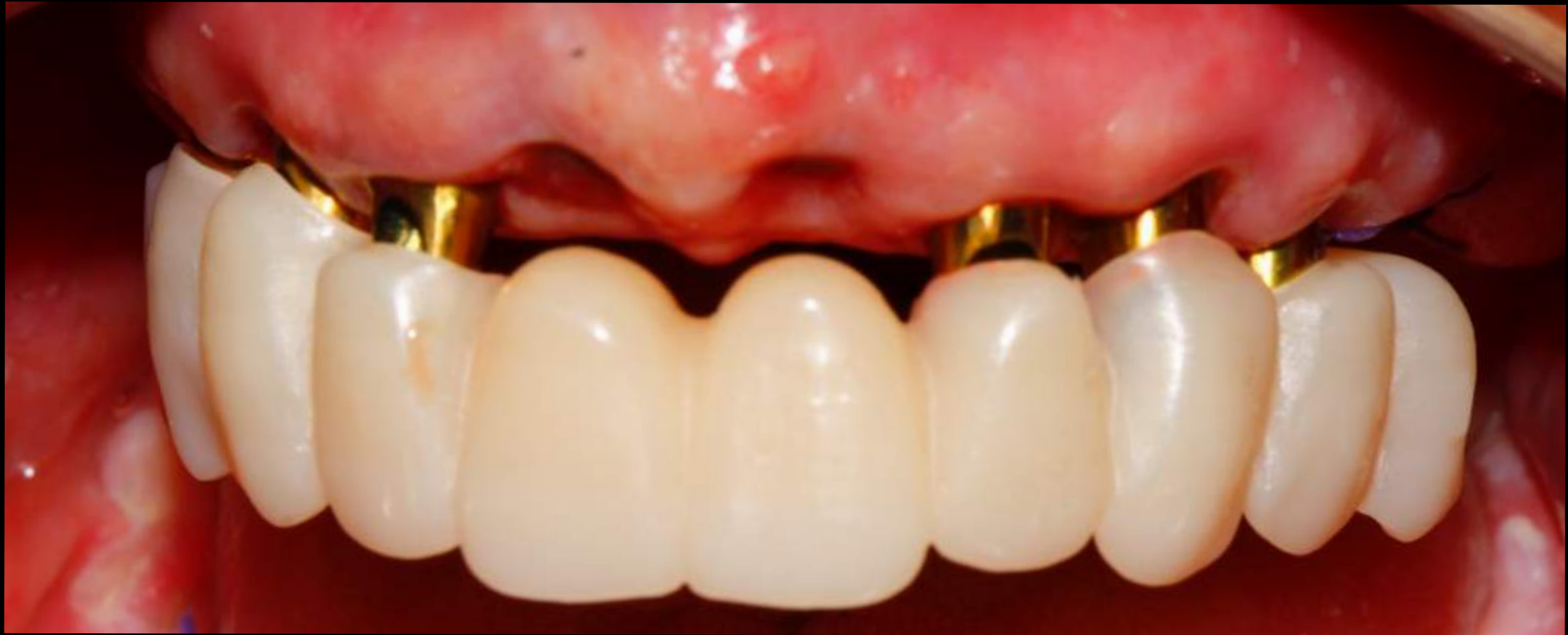ESTHETIC & IMPLANT DENTISTRY

# “TRY IN” OF ABUTMENTS 24 HOUR AFTER SURGERY



*Dr. Alejandro Freer*

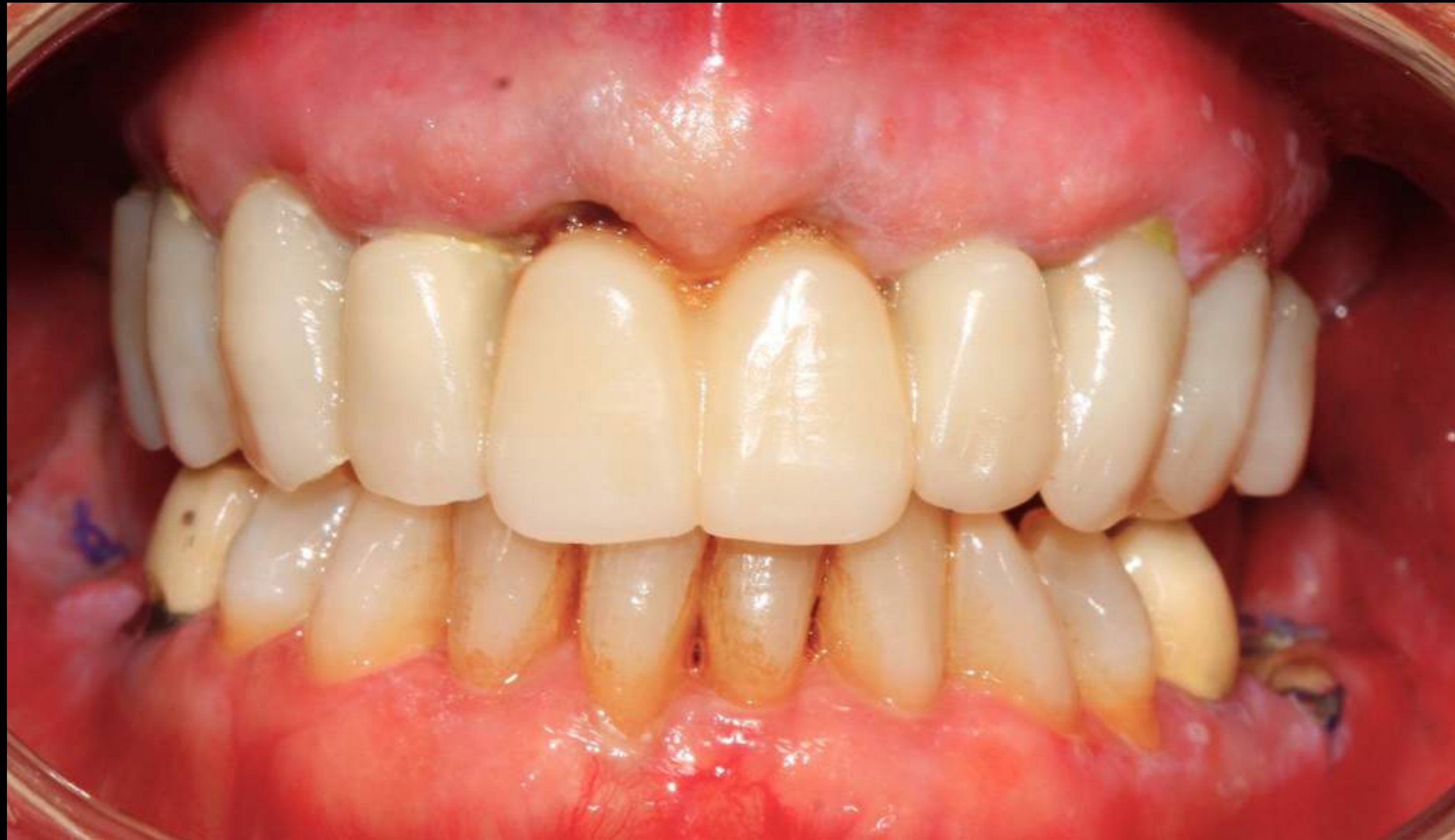ESTHETIC & IMPLANT DENTISTRY



*Dr. Alejandro Freer*

ESTHETIC & IMPLANT DENTISTRY

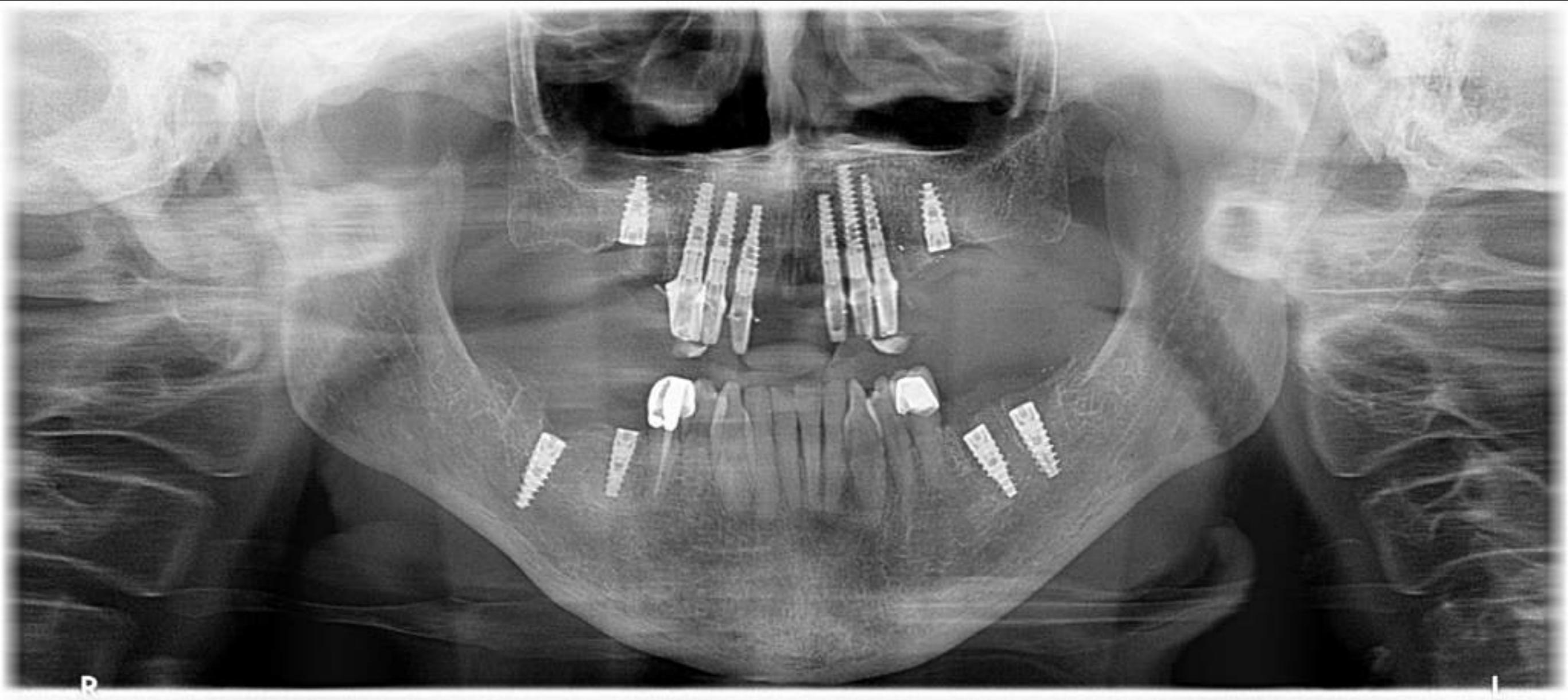
48 HOUR POST -OP



*Dr. Alejandro Freer*

ESTHETIC & IMPLANT DENTISTRY

# POST- OP PANORAMIC X RAY



*Dr. Alejandro Freer*

ESTHETIC & IMPLANT DENTISTRY